



SZABO SCANDIC

Part of Europa Biosite

Produktinformation



Forschungsprodukte & Biochemikalien



Zellkultur & Verbrauchsmaterial



Diagnostik & molekulare Diagnostik



Laborgeräte & Service

Weitere Information auf den folgenden Seiten!
See the following pages for more information!



Lieferung & Zahlungsart

siehe unsere [Liefer- und Versandbedingungen](#)

Zuschläge

- Mindermengenzuschlag
- Trockeneiszuschlag
- Gefahrgutzuschlag
- Expressversand

SZABO-SCANDIC HandelsgmbH

Quellenstraße 110, A-1100 Wien

T. +43(0)1 489 3961-0

F. +43(0)1 489 3961-7

mail@szabo-scandic.com

www.szabo-scandic.com

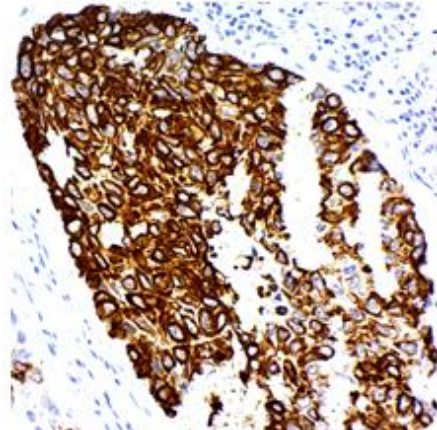
[linkedin.com/company/szaboscandic](https://www.linkedin.com/company/szaboscandic) 

P.O. Box 3286 - Logan, Utah 84323, U.S.A. - Tel. (800) 729-8350 - Fax (435) 755-0015 - www.scytek.com

UltraTek Horseradish Peroxidase

Uses/Limitations: A Ready-to-use streptavidin-horseradish peroxidase enzyme label designed for 3-step immunohistochemistry protocols. Formulated to provide optimal staining with an incubation for 10 minutes. May be used with automated systems, reagent jars, and manual dropping/pipetting.

Uses/Limitations: Not to be taken internally.
 For In-Vitro Diagnostic use only.
 Histological applications.
 Do not use if reagent becomes cloudy.
 Do not use past expiration date.
 Use caution when handling reagent.
 Non-Sterile.



Human Lung stained with DAB and UltraTek Horseradish Peroxidase within an IHC protocol.

Control Tissue: Any well-fixed tissue.

Availability/Contents:


<u>Item #</u>	<u>Volume</u>
ABL008	8 ml
ABL015	15 ml
ABL125	125 ml
ABL500	500 ml
ABL999	1000 ml


Storage: Store at 2-8°C Centigrade. Product is stable for 18 months from date of manufacture.

Procedure:

Allow reagents to come to room temperature before use.


1. Deparaffinize and rehydrate tissue section.
2. If needed, incubate slide in hydrogen peroxide for 10-15 minutes to reduce nonspecific background staining due to endogenous peroxidase.
3. Wash 2 times in buffer.
4. If required, incubate tissue in digestive enzyme.
5. Wash 4 times in buffer.
6. Place slide in protein block (ScyTek's "Superblock") and incubate 5-10 minutes at room temperature to block nonspecific background staining. Note: Do not exceed 10 minutes or there may be a reduction in desired stain.

Storage: 2° C  8° C



ScyTek Laboratories, Inc.
 205 South 600 West
 Logan, UT 84321
 435-755-9848
 U.S.A.

CE 


 Emergo Europe
 Prinsessegracht 20
 2514 AP The Hague, The Netherlands

P.O. Box 3286 - Logan, Utah 84323, U.S.A. - Tel. (800) 729-8350 - Fax (435) 755-0015 - www.scytek.com

7. Wash 1 time in buffer.
8. Apply primary antibody and incubate according to manufacturer's protocol.
9. Wash 4 times in buffer.
10. Place slide in biotinylated link secondary antibody, and incubate per instructions.
11. Wash 4 times in buffer.
12. Place slide in UltraTek Horseradish Peroxidase, and incubate for 10 minutes.
13. Rinse 4 times in buffer.
14. Place slide in appropriate chromogenic substrate and incubate until desired reaction is achieved.
15. Counterstain and coverslip.

Troubleshooting Guide

Overstaining:

1. Concentration of the primary antibody was too high or the incubation time was too long.
2. Temperature during incubation was too high.
3. Incubation time with link antibody or streptavidin/enzyme label was too long.

Nonspecific Background Staining:


1. Rinsing between steps was inadequate.
2. Tissue was allowed to dry with reagents on.
3. Folds in tissue trapped reagents.
4. Tissue contains endogenous enzyme.
5. Tissue contains endogenous biotin.
6. Antigen migrated in tissue.
7. Excessive tissue adhesive on slides.
8. Inadequate blocking with protein block.

Weak Staining:

1. Primary antibody concentration was too low or incubation time was too short.
2. Reagents are past their expiration date.
3. Reagent is reaching the end of its useful life.
4. Counterstain or mounting media were incompatible and dissolved the chromogen reaction product.
5. Room temperature was excessively cool.
6. The primary antibody does not recognize an antigen that survives fixation and embedding in high enough amounts.
7. Excessive incubation with protein block (Super Block or normal serum).

No Staining:

1. Steps were inadvertently left out.
2. There is no relevant antigen in the tissue.
3. Chromogenic substrate does not match enzyme label.
4. One or more components have been inactivated.

Storage: 2° C  8° C



ScyTek Laboratories, Inc.
205 South 600 West
Logan, UT 84321
435-755-9848
U.S.A.




EC REP


Emergo Europe
Prinsessegracht 20
2514 AP The Hague, The Netherlands

P.O. Box 3286 - Logan, Utah 84323, U.S.A. - Tel. (800) 729-8350 - Fax (435) 755-0015 - www.scytek.com

References:

1. Balemans, M. C. M., Ansar, M., Oudakker, A. R., van Caam, A. P. M., Bakker, B., Vitters, E. L., ... van Bokhoven, H. (2014). Reduced Euchromatin histone methyltransferase 1 causes developmental delay, hypotonia, and cranial abnormalities associated with increased bone gene expression in Kleeftstra syndrome mice. *Developmental Biology*, 386(2), 395–407. <https://doi.org/10.1016/j.ydbio.2013.12.016>
2. Celik, O., Ugras, M., Hascalik, S., Aydin, N. E., & Abbasov, T. (2009). Enhanced endometrial response to a magnetic intrauterine device: A preliminary study. *The European Journal of Contraception & Reproductive Health Care*, 14(6), 437–443. <https://doi.org/10.3109/13625180903318259>
3. Çetinel, Ş., Çanılıoğlu, Y. E., Çikler, E., Şener, G., & Ercan, F. (2011). Leukotriene D4 receptor antagonist montelukast alleviates protamine sulphate-induced changes in rat urinary bladder. *BJU International*, 107(8), 1320–1325. <https://doi.org/10.1111/j.1464-410X.2010.09532.x>
4. Chimenti, C., Scopelliti, F., Vulpis, E., Tafani, M., Villanova, L., Verardo, R., ... Frustaci, A. (2015). Increased oxidative stress contributes to cardiomyocyte dysfunction and death in patients with Fabry disease cardiomyopathy. *Human Pathology*, 46(11), 1760–1768. <https://doi.org/10.1016/j.humpath.2015.07.017>
5. Cohen, M., Matteo, E. D., Narbaitz, M., Carreño, F. A., Preciado, M. V., & Chabay, P. A. (2013). Epstein–Barr virus presence in pediatric diffuse large B-cell lymphoma reveals a particular association and latency patterns: Analysis of viral role in tumor microenvironment. *International Journal of Cancer*, 132(7), 1572–1580. <https://doi.org/10.1002/ijc.27845>
6. Feng, J., El-Assal, O. N., & Besner, G. E. (2006). Heparin-binding epidermal growth factor–like growth factor reduces intestinal apoptosis in neonatal rats with necrotizing enterocolitis. *Journal of Pediatric Surgery*, 41(4), 742–747. <https://doi.org/10.1016/j.jpedsurg.2005.12.020>
7. Guler, G., Himmetoglu, C., Jimenez, R. E., Geyer, S. M., Wang, W. P., Costinean, S., ... Huebner, K. (2011). Aberrant expression of DNA damage response proteins is associated with breast cancer subtype and clinical features. *Breast Cancer Research and Treatment*, 129(2), 421–432. <https://doi.org/10.1007/s10549-010-1248-6>
8. Konya, D., Gercek, A., Akakin, A., Akakin, D., Tural, S., Cetinel, S., ... Pamir, M. N. (2008). The effects of inflammatory response associated with traumatic spinal cord injury in cutaneous wound healing and on expression of transforming growth factor-beta1 (TGF-β1) and platelet-derived growth factor (PDGF)-A at the wound site in rats. *Growth Factors*, 26(2), 74–79. <https://doi.org/10.1080/08977190802025339>
9. Marioni, G., Bedogni, A., Giacomelli, L., Ferraro, S. M., Bertolin, A., Facco, E., ... Marino, F. (2005). Survivin expression is significantly higher in pN+ oral and oropharyngeal primary squamous cell carcinomas than in pN0 carcinomas. *Acta Oto-Laryngologica*, 125(11), 1218–1223. <https://doi.org/10.1080/00016480510038194>
10. Marioni, G., Bertolin, A., Giacomelli, L., Marchese-Ragona, R., Savastano, M., Calgaro, N., ... Staffieri, A. (2006). Expression of the Apoptosis Inhibitor Protein Survivin in Primary Laryngeal Carcinoma and Cervical Lymph Node Metastasis. *Anticancer Research*, 26(5B), 3813–3817.
11. Marioni, G., Gaio, E., Giacomelli, L., Marchese-Ragona, R., Staffieri, C., Staffieri, A., & Marino, F. (2005). Endoglin (CD105) expression in head and neck basaloid squamous cell carcinoma. *Acta Oto-Laryngologica*, 125(3), 307–311. <https://doi.org/10.1080/00016480410023047>
12. Marioni, G., Ottaviano, G., Marchese-Ragona, R., Giacomelli, L., Bertolin, A., Zanon, D., ... Staffieri, A. (2006). High nuclear expression of the apoptosis inhibitor protein survivin is associated with disease recurrence and poor prognosis in laryngeal basaloid squamous cell carcinoma. *Acta Oto-Laryngologica*, 126(2), 197–203. <https://doi.org/10.1080/00016480500266685>
13. Mileo, A. M., Di Venere, D., Abbruzzese, C., & Miccadei, S. (2015). Long Term Exposure to Polyphenols of Artichoke (*Cynara scolymus* L.) Exerts Induction of Senescence Driven Growth Arrest in the MDA-MB231 Human Breast Cancer Cell Line [Research article]. <https://doi.org/10.1155/2015/363827>
14. Miret, N., Rico-Leo, E., Pontillo, C., Zotta, E., Fernández-Salguero, P., & Randi, A. (2017). A dioxin-like compound induces hyperplasia and branching morphogenesis in mouse mammary gland, through alterations in TGF-β1 and aryl hydrocarbon receptor signaling. *Toxicology and Applied Pharmacology*, 334, 192–206. <https://doi.org/10.1016/j.taap.2017.09.012>
15. Suren Castillo, S., Doger, M. M., Bolkent, S., & Yanardag, R. (2008). Cholesterol efflux and the effect of combined treatment with niacin and chromium on aorta of hyperlipidemic rat. *Molecular and Cellular Biochemistry*, 308(1), 151–159. <https://doi.org/10.1007/s11010-007-9623-2>

Storage: 2° C  8° C

 ScyTek Laboratories, Inc.
205 South 600 West
Logan, UT 84321
435-755-9848
U.S.A.



Emergo Europe
Prinsessegracht 20
2514 AP The Hague, The Netherlands